

Spodick's Sign: A Helpful Electrocardiographic Clue to the Diagnosis of Acute Pericarditis

[Letter]. Perm J 2014 Winter;18(1):e122

<http://dx.doi.org/10.7812/TPP/14-001>

Re: Masek KP, Levis JT. ECG diagnosis: Acute pericarditis. Perm J 2013 Fall;17(4):e146.
DOI: <http://dx.doi.org/10.7812/TPP/13-044>.

Dear Editor,

We read with great interest the work by Masek and Levis published in a recent issue of *The Permanente Journal*.¹ They describe a classical electrocardiographic evolution of acute pericarditis. In the presented first electrocardiogram (ECG) of Stage I acute pericarditis, we would like to bring to the readers' attention an interesting ECG finding: Spodick's sign (Figure 1).² This sign has been named after our University professor David Spodick, MD, a world-famous physician for his work on the pericardial diseases. It signifies to a downsloping TP segment in patients with acute pericarditis and is present in about 80% of the patients affected with acute pericarditis. The sign is often best visualized in lead II and lateral precordial leads. In addition, Spodick's sign may also serve as an important distinguishing electrocardiographic tool between the acute pericarditis and acute coronary syndrome.³ PR-segment depression when used alone can sometimes be a masquerader, as it can be seen in both acute pericarditis and acute coronary syndrome. However, the presence of PR depression and Spodick's sign is often a giveaway to the diagnosis.^{4,5}

In Masek and Levis's Figure 1 ECG (www.thepermanentejournal.org/issues/2013/fall/5537-acute-pericarditis.html), TP-segment downsloping is clearly apparent especially in leads II, V4-6 with near complete resolution after treatment with nonsteroidal anti-inflammatory drugs (Masek and Levis's Figure 2 [www.thepermanentejournal.org/issues/2013/fall/5537-acute-pericarditis.html]). ❖

Vinod K Chaubey, MD
Department of Internal Medicine, Saint Vincent Hospital, University of Massachusetts Medical School, Worcester, MA
Lovely Chhabra, MD
Department of Cardiovascular Medicine, Hartford Hospital, University of Connecticut, Hartford, CT

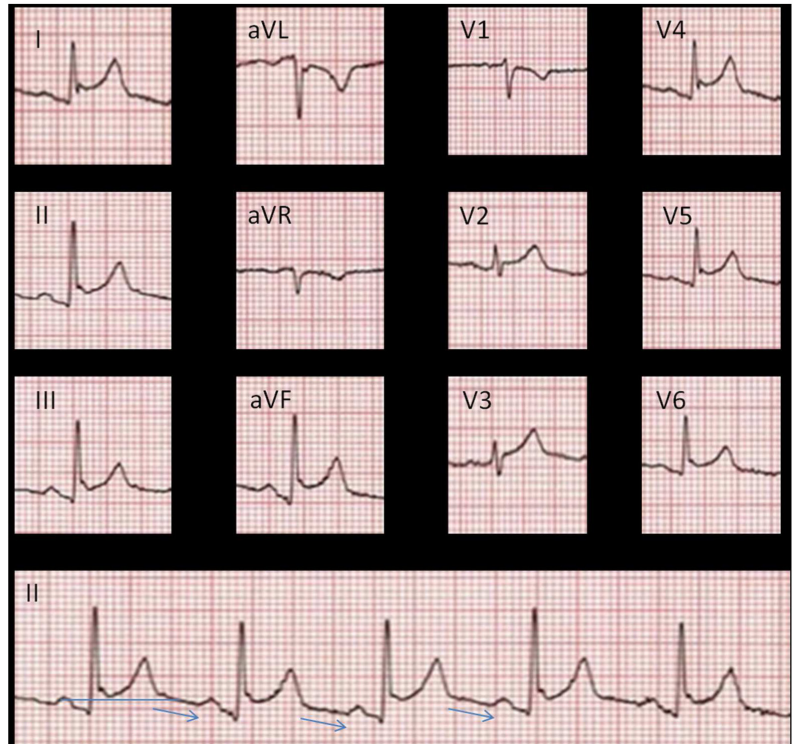


Figure 1. Electrocardiogram (ECG) of a 42-year-old man diagnosed with acute idiopathic/viral pericarditis. ECG represents Stage-1 pericarditis with diffuse PR-segment depression and ST segment elevation (except leads V1 and aVR where PR elevation is noted). Rhythm strip from lead II represents PR depression, ST elevation with slightly downward sloping TP segment (Spodick's sign as depicted by blue arrow). Spodick's sign is often best recognized in lead II as in this ECG illustration.

References

- Masek KP, Levis JT. ECG diagnosis: acute pericarditis. Perm J 2013 Fall;17(4):e146. DOI: <http://dx.doi.org/10.7812/TPP/13-044>.
- Spodick DH. Electrocardiogram in acute pericarditis. Distributions of morphologic and axial changes by stages. Am J Cardiol 1974 Apr;33(4):470-4. DOI: [http://dx.doi.org/10.1016/0002-9149\(74\)90603-1](http://dx.doi.org/10.1016/0002-9149(74)90603-1).
- Makaryus JN, Makaryus AN, Boal B. Spodick's sign. Am J Med 2008 Aug;121(8):693-4. DOI: <http://dx.doi.org/10.1016%2Fj.amjmed.2008.01.020>.
- Chhabra L, Spodick DH. Ideal isoelectric reference segment in pericarditis: a suggested approach to a commonly prevailing clinical misconception. Cardiology 2012;122(4):210-2. DOI: <http://dx.doi.org/10.1159%2F000339758>.
- Chhabra L, Spodick DH. Pericardial disease in the elderly. In: Aronow WS, Fleg JL, Rich MW, editors. Tresch and Aronow's cardiovascular disease in the elderly. 5th ed. Boca Raton, FL: CRC Press; 2014. p 644-68.