

# Abdominal Cutaneous Nerve Entrapment Syndrome (ACNES): A Commonly Overlooked Cause of Abdominal Pain

By William V Applegate, MD, FABFP

## Introduction

Abdominal cutaneous nerve entrapment syndrome (ACNES) may sound like an esoteric condition rarely seen by clinicians but is a common condition. When a patient is seen for abdominal pain without other clinically significant symptoms, ACNES should be high on the list of likely diagnoses.

Beginning in 1792 with J P Frank's description of the condition he named "peritonitis muscularis,"<sup>1</sup> a sampling of pertinent medical literature on this subject<sup>2-9</sup> shows how often the subject has been written about over the years. These articles state that abdominal wall pain is often wrongly attributed to intra-abdominal disorders and that this misdirected diagnosis can lead to unnecessary consultation, testing, and even abdominal surgery, all of which can be avoided if the initial examiner makes the right diagnosis. In a study of 117 patients in 1999, Greenbaum<sup>10</sup> estimated that the amount of money expended on unnecessary workup was \$914 per patient. In 2001, Thompson et al<sup>11</sup> noted that an average of \$6727 per patient was required for previous diagnostic testing and hospital charges. Hershfield<sup>6</sup> listed preliminary diagnoses of patients referred to him as irritable bowel, spastic colon, gastritis, psychoneurosis, depression, anxiety, hysteria, and malingering. Many of these patients were given a psychiatric diagnosis when the actual diagnosis could not be determined. In fact, the most common cause of abdominal wall pain is nerve entrapment at the lateral border of the rectus abdominis muscle;<sup>3,5,8,9,12</sup> Carnett,<sup>3</sup> in the early 20th century, called this syndrome "intercostal neuralgia" and claimed to have seen three patients per week with this diagnosis and as many as three per day in consultation sessions. In my own primary care practice, I have seen one or

two patients with this diagnosis for every 150 patients overall but have seen as many as three such patients per consultation session in a busy evening clinic where 15 or more clinicians were on duty.

Acute cases of ACNES are usually seen in the evening, especially in spring and summer, when people are more active. Chronic and recurrent cases are more likely to be seen in the daytime throughout the year.

To avoid causing the patient unnecessary anxiety and tension, loss of work time, and both the expense and possible hazard of multiple diagnostic procedures, the first physician examining the patient must establish the diagnosis of ACNES if this condition is present. Compiled from my own experience and that of other investigators who have written about ACNES, the information presented here should give readers the tools necessary for diagnosing and treating this condition.

## Pathophysiology of ACNES

Kopell and Thompson<sup>13</sup> stated that peripheral nerve entrapment occurs at anatomic sites where the nerve changes direction to enter a fibrous or osseofibrous tunnel or where the nerve passes over a fibrous or muscular band and that entrapment can be at these sites because mechanically induced irritation is most likely to occur at these locations. Muscle contraction at these sites may add additional insult by direct compression, although I believe that traction on the nerve from muscle activity also is likely. Mechanical irritation causes localized swelling that may injure the nerve directly or compromise the nerve's circulation. Tenderness of the main nerve trunk may be found proximal or distal to the affected portion (Valleix phenomenon). Proximal tenderness may result from vascular spasm or from unnatural traction

**When a patient is seen for abdominal pain without other clinically significant symptoms, ACNES should be high on the list of likely diagnoses.**



**William V Applegate, MD, FABFP**, is a retired SCPMG Family Practice physician from San Diego. He is an Associate Clinical Professor at UCSD Medical School in San Diego, CA.

on the nerve trunk against the point of entrapment. In ACNES, all these mechanisms can be at work.

### Anatomy Pertinent to ACNES

The thoracoabdominal nerves, which terminate as the cutaneous nerves, are anchored at six points (Figure 1):<sup>14</sup> 1) the spinal cord; 2) the point at which the posterior branch originates; 3) the point at which the lateral branch originates; 4) the point at which the anterior branch makes a nearly 90° turn to enter the rectus channel; 5) the point from which accessory branches are given off in the rectus channel, shown (although not labeled) in previously published microphotographs;<sup>15</sup> and 6) skin.

The most common cause of abdominal wall pain is nerve entrapment at the lateral border of the rectus muscle. In the rectus channel, the nerve and its vessels are surrounded by fat and connective tissue that bind the nerve, artery, and vein into a discrete bundle capable of functioning as a unit independently from surrounding tissue. At a point located about three quarters of the way through the rectus muscle (from back to front), there is a fibrous ring that provides a smooth surface through which the bundle can slide. Positioned anterior to the ring, the rectus aponeurosis provides a hiatus for the exiting bundle.

The hypothesis that nerve ischemia is caused by localized compression of the nerve at the level of the ring is deduced from juxtaposition of the soft bundle to the hard ring. Herniation of the bundle through the ring due to too much pressure from behind or from pulling from in front will compress the bundle's vessels and the nerve itself. Too much traction on the bundle from behind or from pulling in front will cause the bundle to be "strummed" against the ring, which then causes irritation and swelling even before herniation occurs.

Anything that increases pressure behind the abdominal wall can cause the bundle to herniate through the fibrous ring and aponeurotic opening. Use of the abdominal muscles can add additional insult. Enlargement of the abdomen from any cause will put the nerves under greater traction. Scar or suture around the nerve in front of the rectus<sup>16-18</sup> can directly compress the nerve or place it under further traction. Disparate motion between skin and muscle will aggravate this situation. Although any main branch of the nerve may become symptomatic, the anterior branches are most likely to be affected, because stretching of the nerve is greatest at the point most distant from its origin (ie, the spinal cord). Because the anterior branches enter the back of the muscle at nearly a right angle, they are more sus-

ceptible to mechanical irritation than are the posterior and lateral branches, which enter the muscle at a more oblique angle. Lateral branches are affected by lateral bending and twisting of the trunk; posterior branches are affected by bending, lifting, and twisting. Accessory branches perforate the muscle wall above and below the main branches but also exit from adjacent muscle mass. These branches are difficult to palpate unless symptomatic and tender to touch.

### Diagnosing ACNES

#### Clinical Presentation

Symptoms of ACNES can be acute or chronic. The acute pain is described as localized, dull, or burning, with a sharp component (usually on one side) radiating horizontally in the upper half of the abdomen and obliquely downward in the lower abdomen. The pain may radiate when the patient twists, bends, or sits up. Lying down may help but sometimes worsens the pain. Younger people, who are usually more physically active than older persons, are more often seen for the first episode of acute pain. The pain may have started during the night but did not cause these patients to miss work the next morning. Nonetheless, they come to the evening clinic because the pain persists, worsens, and causes them to be afraid that they won't be able to work the next day. Young women often express concern about their "ovaries," "kidneys" (the bladder is meant), or both.

Brief discussion of the ovarian complaint here is important because it occurs frequently and is the predominant initial reason for women with ACNES to be seen in the clinic.<sup>16,17,19,20</sup>

Concern about their gonads is uppermost in the minds of young people who have re-

**Symptoms of ACNES can be acute or chronic ... The pain may have started during the night but did not cause these patients to miss work the next morning.**

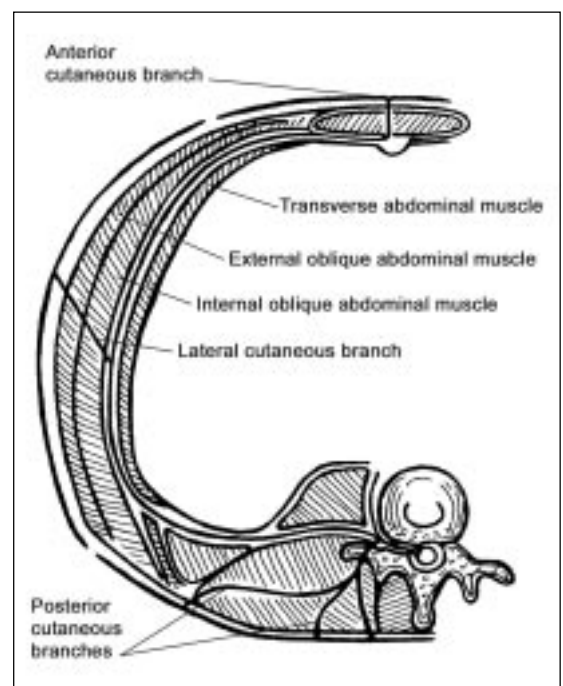


Figure 1. Anatomy of thoracoabdominal nerves.

(Adapted and reproduced by permission of the publisher, of the author, and of the illustrator, Nelva M Bonucchi, from: Applegate WV. Abdominal cutaneous nerve entrapment syndrome. *Am Fam Physician* 1973 Sep;8(3):132-3.<sup>14</sup>)

cently matured sexually. Because the testicles are located in the externally positioned scrotal sac, men have the advantage of being able to examine their testicles easily, whereas women's ovaries, being located inside the abdomen, are inaccessible to examination except by medical personnel. Consequently, women may attribute any abdominal complaint to an ovarian disorder until a different cause of pain is shown. Given a chief complaint of "pain in the ovary," the examiner should certainly examine the ovaries but should remember that this is often the way ACNES clinically manifests itself.

Unfortunately, women are not the only ones to attribute abdominal pain to gynecologic pathology when the source of pain is actually in the abdominal wall. Noting that between 30% and 76% of diagnostic laparoscopic procedures done for pelvic pain show normal tissues, Slocomb<sup>20</sup> expressed concern about surgical exploration with removal of pelvic structures for normal variants in women with chronic pelvic pain when the problem was actually traceable to the abdominal wall. One of my patients was a woman who had surgery first for "ovarian cyst" and then for "adhesions" but still complained of the same pain, which, I discovered, was caused by ACNES.<sup>5</sup> A study of 120 emergency admissions to the hospital for abdominal pain<sup>21</sup> showed that 23 of 24 patients who had abdominal surgery with a positive Carnett's sign (see below) had no intra-abdominal disorder; instead, the pain was traced to the abdominal wall.

Young men with ACNES are often seen in the daytime for a chief complaint of "hernia" or "ulcer," complaints considered more common in men. Older men and women may express concern about cancer (not an unreasonable concern among seniors). These patients may need further examination, even if ACNES caused the pain that brought them to the doctor. A history of multiple abdominal operations should raise suspicion about ACNES. Finding several surgical scars on the abdomen should alert the examiner to this possibility.

Chronic complaints due to ACNES are usually seen during the day in older patients. Medical history in these patients shows that acute exacerbation of pain may occur over several days or weeks and then disappear for varying lengths of time, sometimes for years. One of my male patients with ACNES reported that he had pain intermittently for 47 years.<sup>5</sup> He had long ago decided that the pain was of no great consequence but

was happy to hear my explanation of its cause. If a patient says, "I have this pain in my stomach, and nobody seems able to find the cause," the examiner should immediately think of ACNES.

ACNES-related pain is well localized and usually affects only one side. However, the pain can occur on both sides at the same level (usually in the lower abdomen), or more than one nerve can be affected on opposite sides and at different levels. Pain radiating into the scrotum or vulva suggests involvement at the T12/L1 level, but inguinal or femoral hernia and pain arising from the adductor muscles of the thigh must

be ruled out. Pain and tenderness posterolaterally just below the iliac crest can occur with involvement at the T12/L1 level. This finding is useful because it is present with abdominal wall pain but is absent if the pain arises from inside the abdomen.<sup>3</sup> Pain radiating from T11 and T12 runs at an oblique angle and follows the course of these nerves. Such pain can suggest urolithiasis; however, patients with urolithiasis are usually seen writhing in pain, whereas patients with

**Chronic ACNES patients suffer considerable anxiety and worry that they may have some horrible condition ...**

ACNES tend to lie quietly on the table with their hand placed over the area of discomfort. T11 involvement on the right side may suggest appendicitis, and involvement on either side may suggest ovarian involvement or spigelian hernia; all these conditions should be identified by proper physical examination. Pain on the right side at the T8 or T9 level may suggest cholecystitis or peptic ulcer; however, as Carnett<sup>3</sup> has suggested, deep tenderness is not detected without peritoneal involvement. Pain at the T6, T7, or T8 levels can suggest pleurisy, costochondritis, or slipping rib syndrome (which is probably a form of ACNES caused by traction). Pain and numbness laterally in the thigh and hip may be caused by meralgia paresthetica, mentioned here as a matter of interest because it is also caused by nerve entrapment; in this case, the lateral femoral cutaneous nerve is entrapped between the iliac ligament and the anterosuperior aspect of the iliac spine.<sup>13</sup> For a complete list of conditions other than ACNES that can cause abdominal wall pain, the reader is referred to Carnett,<sup>3</sup> Hershfield,<sup>6</sup> Suleiman and Johnston,<sup>9</sup> Gallegos and Robsley,<sup>17</sup> and Greenbaum.<sup>22</sup>

Chronic ACNES patients suffer considerable anxiety and worry that they may have some horrible condition as yet undiscovered. As a result, they may be given a psychiatric diagnosis (eg, anxiety, somatization, or depression) and therefore often take antidepressant drugs,

tranquilizers, muscle relaxants, or pain relievers. Such a medical history should raise the question of ACNES.

### Physical Examination

A suggestive medical history should direct the examiner to precisely locate the tender spot by asking the patient, "Where exactly is the pain?" The patient usually responds by placing several fingers over the area, whereupon the examiner says, "Show me with one finger." As patients place a fingertip on the exact spot, pushing a little harder to find it, they usually say, "Right here!" and flinch as the tender spot is pressed.

To proceed beyond this point in the examination, the examiner must be familiar with the exact location of each neuromuscular foramen. To do this, the examiner should practice finding these depressions on his or her own abdomen and on someone else. In addition, each time a patient's abdomen is examined for any reason, the examiner should feel for these aponeurotic openings; their size differs widely among persons. Larger openings, usually found in obese patients, are easier to palpate and provide familiarity with the feel of a foramen so that the examiner will know what to look for when presented with smaller dimensions in another patient.

The anterior exits are easiest to feel and are often best felt with the patient standing and pushing the abdomen out: T10 is at the lateral edge of the rectus margin at the level of the umbilicus; T12/L1 is at the level of the internal inguinal ring; and T11 is halfway between T10 and T12/L1 at the rectus margin, which is closer to the midline for these last two points. T8 is at the junction of the rib margin (eighth rib) and the lateral rectus; and T9 is halfway between T8 and T10. T6 and T7 are located where their respective ribs meet the edge of the rectus muscle.

The lateral muscular foramen are more difficult to palpate and are most easily felt with the patient leaning away from the side being palpated. Firmer pressure with the finger is required. These openings are in the vertical groove found at the junction between the back and abdominal muscles. Lateral T10 is located at the point where the 10th rib meets the groove. Lateral L1 can be felt in the groove just above the iliac crest, and the other two lateral branches are in the groove between T10 and L1. The examiner should not be discouraged if finding such a foramen seems difficult; they are easier to find when they are symptomatic.

Posterior foramina are found in the groove between the paravertebral muscles and the more lateral back muscles. These, too, are more difficult to palpate, but the muscular depression at that site is easier to find when

it is associated with symptoms and localized tenderness.

A description of how the anterior foramina actually feels will help examiners to find them. Approaching the opening with the hand resting lightly on the abdomen from the lateral side, the middle fingertip is moved over the rounded edge of the rectus, where the examiner may feel an oval-shaped depression oriented horizontally but sloped posteriorly on the edge of the rectus at levels T8 through T12/L1. As pressure from the straight finger tuft is gradually increased, the examiner feels, in order: 1) firm skin; 2) spongy-textured subcutaneous fat; 3) the oval, firm ring of the aponeurosis

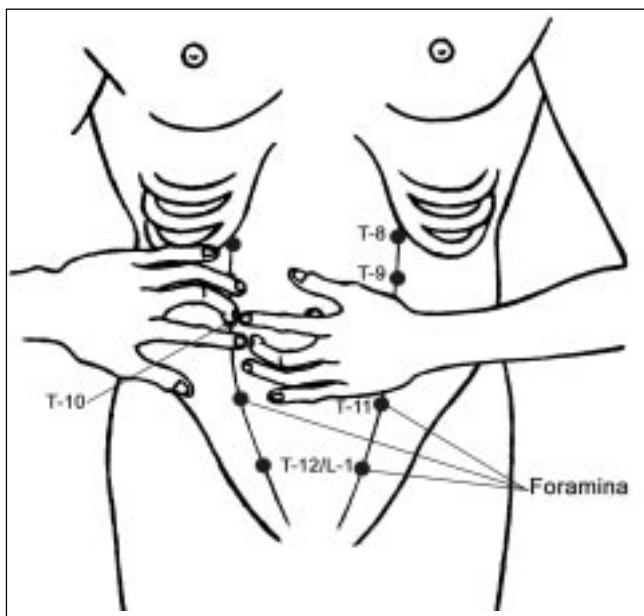


Figure 2. "That's it!" When localizing own pain, patient points left index finger, for example, to T-10 opening. Clinician reaches in from lateral side to confirm location is a neuromuscular foramen.

containing a morbilliform mass of fat (the fatty plug); and 4) deep to these structures, the firm, round ring which prevents further invasion of the channel. The aponeurotic openings for these nerves may vary in size from that which barely admits the tip of the finger tuft to a size that allows placement of the entire finger tuft into the depression. The ring felt deep in the channel may feel too tough to push beyond. The fatty plug varies in size from 2 mm to 2 cm, depending on how dilated the aponeurotic openings have become. In practical terms, it is the aponeurotic openings and enclosed fatty plug that are most easily distinguished from surrounding tissue. These fatty plugs can often be pal-

pated in asymptomatic persons and may normally feel uncomfortable to firm palpation, attesting to the fact that their location predisposes them to trauma. The anterior openings of T6, T7, and T8 feel more triangular and are oriented in the anteroposterior plane across the posteroinferior part of the rib tip. Firmer pressure against the rib tip is necessary to feel these openings. The same technique can be advised for the lateral and posterior openings, which usually will admit only 2 mm to 3 mm of finger tuft. Accessory nerve exits are located 2 mm to 3 mm above or below the main branch exits or over adjacent muscle and usually cannot be palpated with certainty unless symptomatic.

The examiner now must confirm that the point located by the patient is actually a nerve exit. With the hand resting gently on the patient's abdomen lateral to the tender spot indicated by the patient's finger, the examiner's straightened middle finger can be used to displace the patient's finger medially by advancing in a tiny, circular motion. As finger pressure is gradually increased, the patient with ACNES will recoil or grab the examiner's hand, exclaiming, "That's it!" (Figure 2).<sup>9</sup> (Hershfield<sup>6</sup> calls this the Hover Sign.) From the location of the symptomatic spot and from the feel of the muscular foramen, the examiner should be satisfied that this is a genuine example of ACNES.

To further differentiate the source of the pain, Carnett's sign should be elicited.<sup>3</sup> While in supine position with the arms crossed over the chest, the patient should be asked to raise his or her head or feet off the table while the examiner pushes on the tender spot. If splinting the muscles in this manner reduces the amount of pain, the source is probably intra-abdominal. If the pain is in the abdominal wall, splinting the muscles will not reduce the pain and may actually increase it.

The "pinch test"<sup>23</sup> can also be used if the examiner is initially unable to identify the side on which the pain originates. This test consists of picking up the patient's skin and subcutaneous fat with the thumb and index finger, first on one side of the midline of the abdomen and then on the other side. The patient will state whether one side hurts more than the other. Cotton and pinprick technique can be used to check for hypoesthesia or hyperesthesia around the pain site, and Knockhaert<sup>23</sup> notes that electromyographic studies of the affected nerve show abnormalities in 60% of patients studied (although this author<sup>23</sup> admitted that the procedure has low sensitivity). Carnett<sup>3</sup> noted sensitivity along the proximal portion of the affected nerve (Valleix phenomenon).

Practically, if the area of tenderness can be localized to one of the palpably identifiable nerve exits, these other tests (with the possible exception of Carnett's sign) are probably only of academic interest.

Having come this far in the examination, if either the patient or the examiner needs further convincing of the ACNES diagnosis, local injection of an anesthetic agent is appropriate (described later under "Treatment"). Complete relief of pain by the anesthetic agent establishes the diagnosis.

### Recommended Treatment for ACNES

A properly administered local injection of an anesthetic agent completely relieves the pain of ACNES. Technique is critical for both diagnosis and treatment, and the tendency is to inject too deeply.

The patient is given an injection of .5 mL to 1 mL of a 2% lidocaine solution (or its equivalent) using a #21 or #22 needle of length appropriate for the thickness of the subcutaneous tissue present. A needle of this size best allows the clinician to feel the anatomic landmarks while administering the injection, but a #25 or #26 needle can be used if the clinician is sufficiently familiar with the landmarks. For patients with a thick layer of adipose tissue, a spinal needle may be needed to reach the front of the muscle.

The injection serves two purposes: to relieve pain and to reduce herniation of the neurovascular bundle through the fibrous ring. Sequentially as the needle is introduced, the clinician feels resistance to the needle from the patient's skin, the nonresistant texture of the subcutaneous fat, and then mild resistance to the needle from the aponeurosis and fatty plug. (The needle should not be introduced deeper than this level; deeper injection can cause ecchymosis and may increase pressure on the neurovascular bundle in an already tight fibromuscular channel.) At this point, the needle should already be in the center of the channel and fatty plug and just beneath the aponeurosis. If the examiner is unsure that the needle is positioned correctly, it may be pulled back into the subcutaneous fat to prepare for another attempt at placing the tip of the needle beneath the structures in front of the fibrous ring.

As mentioned above, landmarks of the pertinent structures can best be felt with the patient standing and bearing down, and the injection can be given in this position. However, if the patient is more comfortable lying down, the injection may alternatively be given in this position.

To be sure the needle is positioned precisely (Figure 3)<sup>24</sup> at the correct place for injection, the examiner should

**Complete relief of pain by the anesthetic agent establishes the diagnosis.**

first place the middle finger of one hand in the aponeurotic opening and then, without lifting the finger off the skin, move the fingertip inferiorly, cleanse the skin with alcohol using the other hand, and with that hand introduce the needle above the tip of the examining finger. When the needle is properly situated beneath the aponeurosis, the clinician stabilizes the syringe for injection by gripping it using the same hand used to locate the opening. The patient should be asked not to breathe during aspiration and injection. These instructions may seem rudimentary; however, if followed exactly, they will guarantee success in diagnosing and treating ACNES.

A patient who feels faint after receiving the injection should be allowed to lie down until s/he feels better; otherwise, the patient should be encouraged to move about the room. When the syringe has been disposed of and the patient has taken a few steps, the clinician should ask if the patient still feels pain. If the injection has been effective, patients often volunteer, with a look of amazement on their faces, "It's gone!" Clinical response sometimes takes more time than this if the injection has been made slightly off the locus. If the response is mediocre and the clinician suspects the reason may be because the injection was not placed accurately, a second injection may be attempted after about ten minutes or on another day. Occasionally, a patient reports relief from pain upon arriving home. In such circumstances, a patient should be encouraged to return to the clinic if the pain recurs or if new symptoms arise.

Mehta<sup>4</sup> and McGrady<sup>17</sup> used a Teflon-coated needle with exposed tip to locate the nerve by electrical stimulation. I tried this technique with several patients and found the procedure cumbersome and time-consuming. After learning to locate the nerve as described here, clinicians can place the injection accurately in minutes without using a nerve locator.

In many patients, one injection gives prolonged relief or may sufficiently reassure younger patients that the condition is benign and will not require another visit unless another injection is needed for pain relief. Older persons should be advised to return whenever the pain recurs or when other symptoms develop so that underlying causes can be addressed if necessary. Because repeat injection requires only a few minutes in patients who have already been evaluated, these patients may often be scheduled for a same-day ap-

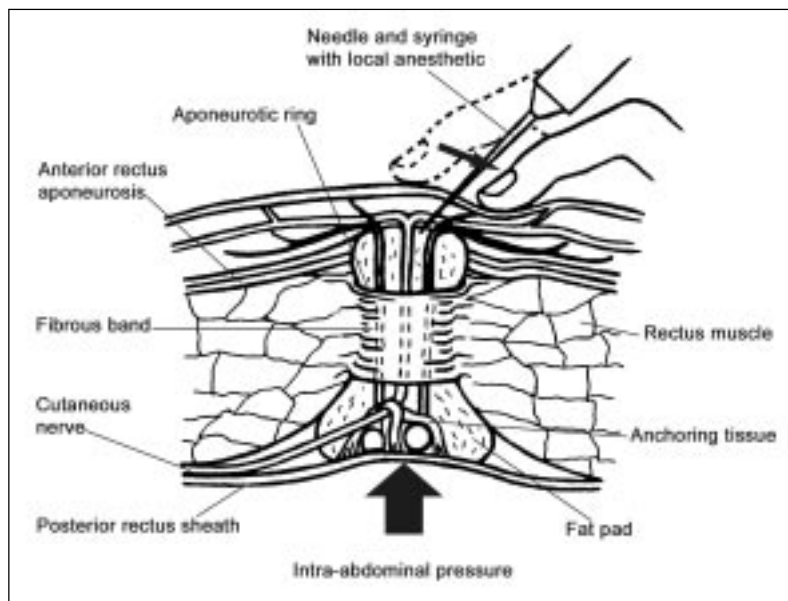


Figure 3. Clinician locating the precise injection site.

(Adapted and reproduced by permission of the publisher, of the authors, and of the illustrator, Marjorie Domenowske, from: Bonica JJ, Jobansen K, Loeser JD. Abdominal pain caused by other diseases. In: Bonica JJ, editor. The management of pain. 2nd ed Vol 2. Philadelphia: Lea & Febiger; 1990. p 1254-82.<sup>24</sup>)

pointment, even to evaluate new associated symptoms. An alternative is to schedule three return appointments a few days apart, a tactic that gives patients the option to cancel the appointment if they do not think they need it. Some patients need multiple injections to eliminate the pain completely, but these patients seldom need more than four or five injections. Each injection should provide relief for a longer and longer time until no more are needed. For patients who tolerate local anesthesia well but must return every few weeks for another injection, alternative regimens are available.

The clinician must first decide whether further evaluation is justified. Does the patient have musculoskeletal conditions (eg, scoliosis or one short leg) that might subject a particular nerve to undue traction? Especially in older patients, are underlying medical problems causing abdominal enlargement? If for any reason the pain is recurrent or persistent, it can be treated by destroying the symptomatic portion of the nerve. Some patients with ACNES have nerve entrapment in an abdominal scar.<sup>6,16-18</sup> Excising this part of the scar or removing the suture from around the nerve<sup>17</sup> may solve the problem by two mechanisms: 1) relief of direct compression of the nerve and 2) relief of dis-

**In many patients, one injection gives prolonged relief or may sufficiently reassure younger patients that the condition is benign ...**

tal traction on the nerve, especially with disparate motion between the abdominal wall and the skin. The diagnosis of nerve entrapment in a scar is suggested by exacerbation of the pain from pinching the scar or by moving the scar across the underlying muscle. For nerve entrapment under the aponeurosis, injection of phenol or absolute alcohol is an option. Phenol, 5%-7% 1 mL, has been used by some investigators;<sup>4,12,17</sup> however, either because the injection was given too deeply or because they were side effects of the phenol, pain and systemic effects occurred frequently. In my experience, using 1 mL of absolute alcohol mixed with 0.5 mL of a 2% lidocaine solution achieves a good result and causes minimal local pain. Because lidocaine gives immediate relief and prevents any burning sensation from the alcohol when it is first introduced, use of lidocaine helps the clinician to decide whether the injection was properly placed. A phone call from the patient after a few days is all that is needed to confirm treatment success. Only once have I reinjected alcohol into a patient who had only partial relief from the previous injection. Surgery also is an option, although I would consider it only for patients who had scar involvement or who for some reason could not tolerate alcohol injection. The surgical procedure should be done with the patient under local anesthesia so that the patient can state whether traction on the nerve duplicates the symptoms. If this is the case, the nerve should be severed at the front of the muscle to release distal traction.

Some investigators<sup>7,12,25,26</sup> have recommended use of corticosteroid drugs as part of the local anesthetic injection.

Use of corticosteroid drugs is theoretically valuable because some inflammation is seen in ACNES; however, injection of corticoid drugs into muscles can sometimes cause considerable pain, and tissue atrophy can occur with repeated injection. Injection with lidocaine and alcohol has worked well in my practice, and I see no compelling reason to add corticoid agents to the regimen.

Other treatment modalities may temporarily relieve pain of ACNES. Precise application of an ice cube wrapped in a thin washrag can help by acting as a local anesthetic and by reducing swelling around the nerve. Application of an elastic bandage for counterpressure may be helpful. Heat applications may relieve associated muscle spasm.

Most of these recommendations for treatment can be applied to the lateral, posterior, and accessory nerves. In fact, these recommendations could, theoretically, be applied to any other anatomic area where nerves pass through muscles or other tight structures. I strongly suspect that the anatomic areas that Janet Travell called "trigger points"<sup>27</sup> are actually areas where sensory nerves are trapped in muscles that are in spasm. Acupuncture points may also be located at nerve exits.<sup>13</sup> My limited experience with acupuncture suggests that these points can be located by identifying a sensitive depression in the underlying muscle.

### Summary and Conclusions

Over many years, investigators have warned their readers that pain in the abdominal wall is too often misdiagnosed as intra-abdominal pain and that the time and effort spent looking for the cause (which is literally right under their fingertips) are totally unjustified and may cause the patient considerable anxiety and even unnecessary surgery. The most common cause of abdominal wall pain is nerve entrapment at the lateral border of the rectus muscle.

In 1926, Carnett<sup>3</sup> called this condition "intercostal neuralgia." However, recent studies of the anatomy and histopathology of this condition indicated that it is not so much an inflammatory condition as a matter of nerve entrapment. Accordingly, I prefer the name abdominal cutaneous nerve entrapment syndrome (ACNES). This condition is diagnosed and treated by local anesthetic injection into the muscular channel through which the affected nerve passes. This article discusses in detail how to identify the muscular neuroforamina by palpation as well as the specific technique for injecting them.

**Almost everyone who has written about abdominal wall pain overlooks the diagnosis of ACNES ...**

<b>Practice Tips</b>
The most common cause of abdominal wall pain is nerve entrapment at the lateral border of the rectus muscle.
Ask the patient, "Where exactly is the pain?" "Show me with one finger."
Diagnosed and treated by local anesthetic injection into the muscular channel through which the affected nerve passes.
The injection serves two purposes: to relieve pain and to reduce herniation of the neurovascular bundle through the fibrous ring.
Precise application of an ice cube in a thin washrag can help by acting as a local anesthetic and by reducing swelling around the nerve.
Application of an elastic bandage for counterpressure may be helpful.
Heat applications may relieve associated muscle spasm.

Almost everyone who has written about abdominal wall pain overlooks the diagnosis of ACNES while admonishing the medical profession against subjecting patients to unnecessary tests, but each writer also says that if a patient does not respond to the usual treatments, the patient should be further evaluated for underlying contributing causes. This instruction is particularly important for older patients. Diagnostic procedures for these patients are ultimately a matter of clinical judgment, but certainly clinicians and patients can be spared much trouble if the diagnosis of ACNES is established at the first visit. The information given in this article should make that early diagnosis of ACNES possible. Srinivasan and Greenbaum<sup>22</sup> feel that an ACNES patient monitored very closely for three months without convincing evidence that local anesthetic injection or other treatment has really helped should receive further study for visceral disease. Obviously, if new symptoms arise suggesting visceral disease, further diagnostic evaluation is justified at any time even though the treatment for ACNES seems to be effective. ❖

#### Acknowledgments

*The clinical research on which this review article was based was approved by the Institutional Review Board of the Southern California Permanente Medical Group.*

*Juan Domingo provided original adaptations of the illustrations.*

#### References

1. Cited in: Murray GR. An address on myofibrositis as a simulator of other maladies. *Lancet* 1929 Jan 19;1:113-5.
2. Cyriax EF. On various conditions that may simulate the referred pains of visceral disease, and a consideration of these from the point of view of cause and effect. *Practitioner* 1919;102:314-22.
3. Carnett JB. Intercostal neuralgia as a cause of abdominal pain and tenderness. *Surg Gynecol Obstet* 1926;42:625-32.
4. Mehta M, Ranger I. Persistent abdominal pain. Treatment by nerve block. *Anaesthesia* 1971 Jul;26(3):330-33.
5. Applegate WV. Abdominal cutaneous nerve entrapment syndrome. *Surgery* 1972 Jan;71(1):118-24.
6. Hershfield NB. The abdominal wall. A frequently overlooked source of abdominal pain. *J Clin Gastroenterol* 1992 Apr;14(3):199-202.
7. Peleg R. Abdominal wall pain caused by cutaneous nerve entrapment in an adolescent girl taking oral contraceptive pills. *J Adolesc Health* 1999 Jan;24(1):45-7.
8. Oesch A, Kupfer K, Bodoky A. [Intercostal nerve syndrome]. [Article in German]. *Swiss Surg* 2001;7(2):82-5.
9. Suleiman S, Johnston DE. The abdominal wall: an overlooked source of pain. *Am Fam Physician* 2001 Aug 1;64(3):431-8.
10. Abdominal wall pain easily differentiated from visceral origin. *Gastroenterology Observer* 1990 Nov-Dec;9(6):1,8.
11. Thompson C, Goodman R, Rowe WA. Abdominal wall syndrome: a costly diagnosis of exclusion. *Gastroenterology* 2001 Apr;120(5 Suppl 1):A637.
12. Doouss TW, Boas RA. The abdominal cutaneous nerve entrapment syndrome. *N Z Med J* 1975 May;81(540):473-5.
13. Kopell HP, Thompson WA. *Peripheral entrapment neuropathies*. Malabar (FL): Robert E. Kreiger Publishing; 1976. p 1-7, 85-8.
14. Applegate WV. Abdominal cutaneous nerve entrapment syndrome. *Am Fam Physician* 1973 Sep;8(3):132-3.
15. Applegate WV, Buckwalter NR. Microanatomy of the structures contributing to abdominal cutaneous nerve entrapment syndrome. *J Am Board Fam Pract* 1997 Sep-Oct;10(5):329-32.
16. Sippo WC, Burghardt A, Gomez AC. Nerve entrapment after Pfannenstiel incision. *Am J Obstet Gynecol* 1987 Aug;157(2):420-1.
17. McGrady EM, Marks RL. Treatment of abdominal nerve entrapment syndrome using a nerve stimulator. *Ann R Coll Surg Engl* 1988 May;70(3):120-2.
18. Gallegos NC, Hobsley M. Abdominal wall pain: an alternative diagnosis. *Br J Surg* 1990 Oct;77(10):1167-70.
19. Thomson WH, Dawes RF, Carter SS. Abdominal wall tenderness: a useful sign in chronic abdominal pain. *Br J Surg* 1991 Feb;78(2):223-5.
20. Slocumb JC. Neurological factors in chronic pelvic pain: trigger points and the abdominal pelvic pain syndrome. *Am J Obstet Gynecol* 1984 Jul 1;149(5):536-43.
21. Thomson H, Francis DM. Abdominal-wall tenderness: a useful sign in the acute abdomen. *Lancet* 1977 Nov 19;2(8047):1053-4.
22. Srinivasan R, Greenbaum DS. Chronic abdominal wall pain: a frequently overlooked problem. Practical approach to diagnosis and management. *Am J Gastroenterol* 2002 Apr;97(4):824-30.
23. Knockaert DC, Boonen AL, Bruyninckx FL, Bobbaers HJ. Electromyographic findings in ilioinguinal-iliohypogastric nerve entrapment syndrome. *Acta Clin Belg* 1996;51(3):156-60.
24. Bonica JJ, Johansen K, Loeser JD. Abdominal pain caused by other diseases. In: Bonica JJ, editor. *The management of pain*. 2nd ed. Philadelphia: Lea & Febiger; 1990. p 1254-82.
25. Sharf M, Shvartzman P, Farkash E, Horvitz J. Thoracic lateral cutaneous nerve entrapment syndrome without previous lower abdominal surgery. *J Fam Pract* 1990 Feb;30(2):211-2, 214.
26. Tung AS, Tenicela R, Giovanitti J. Rectus abdominis nerve entrapment syndrome. *JAMA* 1978 Aug 25;240(8):738-9.
27. Travell JG, Simons DG. *Myofascial pain and dysfunction: the trigger point manual*. Baltimore: Williams & Wilkins; 1983-92.

**... if new symptoms arise suggesting visceral disease, further diagnostic evaluation is justified ...**