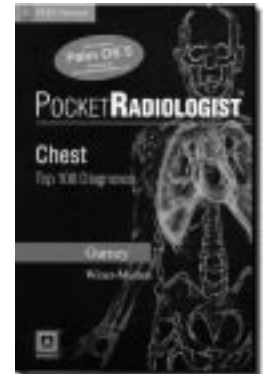


Pocket Radiologist: Chest: Top 100 Diagnoses

by Jud W Gurney, MD, Helen T Winer-Muram, MD

Review by Roxana Covali, MD



Philadelphia: WB Saunders; 2002. ISBN: 0721697046
339 pages; \$59.95

This wonderful book is appropriately dedicated to radiologists, pulmonary physicians, surgeons, and all physicians who use chest x-ray films and related images. Gurney's *Pocket Radiologist* addresses the 100 most common radiologic diagnoses of the chest.

Most diagnoses are discussed in a structured, three-page format that includes key clinical facts, imaging findings, differential diagnosis, pathology, clinical issues, selected references, and two high-resolution images of the chest—one radiograph and one computed tomography (CT) image. For diagnoses that require more detailed explanation, the chest radiograph is replaced by a full-color, computer-generated image that clarifies relevant aspects of anatomy and pathology.

Key clinical facts are presented to illustrate and explain the diagnosis. Synonyms for the diagnosis also are listed. Imaging findings are presented with descriptions of general features expected to be seen on chest radiographs, CT and high-resolution CT (HRCT) scans, and magnetic resonance imaging (MRI) scans. Obstetric ultrasonograms are presented to show bronchial atresia in utero; and images made by using radioactive isotopes are included to illustrate goiter, extramedullary hematopoiesis, or toxic inhalation.

All findings from chest radiographs and CT scans are thoroughly discussed with specific and nonspecific features; percentage of common findings and complications; early radiographic manifestations; length of time to resolution; and recommendations for obtaining earlier imaging studies for comparison. The usefulness of other imaging techniques also is clearly explained. Each diagnosis is presented with recommendations for or against imaging—for example, whether to supplement chest radiography with CT studies to characterize a mass and its relation to surrounding structures.

Differential diagnoses are intelligently organized and are compared with the final diagnosis. Pathology subsections present pathogenesis; gross and microscopic pathology; and prevalence of abnormalities. Clinical issues discussed include disease presentation, natural

history, treatment, and prognosis. For example, discussion of fungal pneumonia includes not only symptoms but also the geographic distribution and source of specific fungi. Treatment is clearly presented. Discussion of prognosis includes both median survival rate and mortality rate. Two or three selected references from major medical journals through 2002 are listed at the end of every diagnosis.

The book is well organized into 14 sections ranging from the airspace to the chest wall.

The *Airspace* section has 18 well-chosen diagnoses. Imaging findings are well detailed for pneumonia, fungal pneumonia, and in particular, for AIDS. The clinical presentation of eosinophilic lung disease is exceptionally well described as is the differential diagnosis of neurogenic pulmonary edema. The differential diagnosis and clinical presentation of viral pneumonia are thoroughly discussed. General pathologic findings in immunocompromised hosts are well described.

The *Airways* section nicely describes nine diseases, including tracheal disease (a commonly overlooked diagnosis). Other well-presented sections discuss imaging findings, differential diagnosis, and clinical issues in amyloidosis; imaging findings for bronchiectasis and cystic fibrosis; and disease of small airways.

The book carefully describes 14 types of *interstitial disease*: sarcoidosis, rheumatoid arthritis, Langerhans cell histiocytosis, asbestosis, and pneumoconiosis (from coal and silica).

Helpful sections describe radiologic and clinical manifestations of drug reaction; lymphangitic carcinomatosis; systemic lupus erythematosus; and diffuse interstitial pneumonia.

The *Mediastinum* section describes diagnosis of 15 conditions, including mediastinal germ tumor, lymphoma (Hodgkin's, non-Hodgkin's, and posttransplant lymphoproliferative disorder), paraneoplastic syndromes, and nerve sheath tumors. Imaging findings and pathology are well detailed, especially for nerve sheath tumors.

The high-quality, appropriately selected images as well as the substantial amount of information about each diagnosis make this book both valuable and practical.

Roxana Covali, MD, is a radiologist at the Elena Doamna Obstetrics and Gynecology University Hospital in Iasi, Romania. She also assists in teaching histology at the Gr. T. Popa University of Medicine and Pharmacy in Iasi, Romania. E-mail: grcovali@telebit.ro.

An impressive chapter about *carcinoma* includes a subsection on each of three topics: lung cancer staging, missed diagnosis of lung cancer, and radiation therapy. The subsection on lung cancer staging discusses interpretation of CT findings; accuracy of CT-based staging; method of adrenal evaluation; the TNM method of staging; and survival rates in relation to staging. The authors emphasize that imaging findings should be confirmed surgically.

The subsection on missed diagnosis of lung cancer describes a hierarchy of errors and discusses overdiagnosis bias, National Cancer Institute (NCI) lung cancer detection programs, and the role of CT screening.

The section on *nodules* describes five diseases, including solitary pulmonary nodules (discussed most comprehensively). Imaging findings of metastases—especially patterns of metastases shown on chest radiographs—are explained clearly. Arteriovenous malformations are vividly illustrated by a digital subtraction angiogram.

The remaining sections also are well done: *Pleura* which describes nine entities ranging from effusion to metastasis; *Hyperinflation and cysts*, in which alpha 1-antitrypsin deficiency is the most detailed of four diagnoses; *Heart and pericardium*, which includes calcifications and detecting abnormal position or displacement of pacemaker and defibrillator leads with perforation

or infection; *Pulmonary artery* and *Aorta* sections, which discuss four entities, including aortic aneurysm and dissection; *Trauma*, which describes aortic transection, tracheobronchial rupture, and three other conditions; and a chapter which describes use of a *portable ICU* to treat any of four disease entities. Use of various tubes and catheters (endotracheal, nasogastric, tracheostomy, chest) in normal and abnormal situations is explained exceptionally well. The *Chest wall* section discusses five diagnoses.

My three small criticisms of this book are that it contains too many abbreviations; that the disease entities discussed in every chapter are not alphabetically ordered; and that it contains too little information on congenital heart malformation. Notwithstanding these minor criticisms, however, the book ends with a well-constructed, comprehensive index of diagnoses—and this useful feature can compensate substantially for the lack of alphabetic ordering of diagnoses within each chapter.

The high-quality, appropriately selected images as well as the substantial amount of information about each diagnosis make this book both valuable and practical. As a final touch, a CD-ROM is provided for conveniently transferring information (including some color illustrations) from the main text to a personal digital assistant (PDA) device. ❖

The Habit of Reading

To acquire the habit of reading
is to construct for yourself a refuge
from almost all the miseries of life.

—W Somerset Maugham, 1874-1965, British novelist, playwright, and short-story writer