



By A. Bernard Gray, MD  
Nathan Meadoff, MD

Commentary by Jerry L. Schilz, MD

## Kaiser Permanente Medicine 50 Years Ago: Fat Embolism

***This is the third in this series of reprints from a quarterly publication, entitled The Permanente Foundation Medical Bulletin, which Morris Collen edited from 1943 to 1953. This entry (from Vol.1(1); July 1943) is a scholarly review of fat embolism (with four brief case reports) by Bernard Gray and Nathan Meadoff. The topic had become important during WWII with the rise in traumatic injuries. Dr. Collen was involved in the writing of the article and as the interpreter of the electrocardiograms. Jerry Schilz, Chief of Orthopedic Surgery at the Southern California Baldwin Park facility, has written an analysis and update. His comments point out the continued timeliness of Drs. Gray and Meadoff's article as well as the ongoing enigmas of fat embolism.***

### Fat Embolism

Cases of fat embolism are of particular interest at the present time with the increase of traumatic injuries due to the expansion of industry and to war casualties. For this reason we herein present two cases of fat embolism and review our present knowledge of the subject.

The phenomenon of fat embolism has been extensively reviewed in literature which dates as far back as 1669, when Lower<sup>1</sup> reported his experiments with intravenous injections of milk into dogs. Magendie<sup>2</sup> in 1821, noted death from asphyxia and pulmonary edema in animals a few minutes after injection of olive oil into the blood stream. Z[e]nker<sup>3</sup> in 1862, was the first to recognize fat embolism in the human following a crush injury to the chest. The classical clinical account in American literature was presented by Warthin<sup>4</sup> in 1913. A summary of the literature was recorded by Vance<sup>5</sup> in 1930, Groskloss<sup>6</sup> in 1935, and Scuderi<sup>7</sup> in 1938.

Vance reclassified conditions contributing to fat embolism into two main categories:

1. "The true etiological factors".
  - (a) Trauma to the osseous system (ie, fractures of the bones, jarring of skeleton, orthopedic operations),
  - (b) Trauma to subcutaneous and intermuscular fat,
  - (c) Trauma to fatty viscera.
2. Agents which have doubtful etiological significance, such as:
  - (a) Burns,
  - (b) Postmortem processes,
  - (c) Poisons,
  - (d) Natural causes of death.

### Etiology and Pathogenesis

Bisgard<sup>8</sup> considers three factors in bone surgery necessary to produce fat embolism: (a) free fluid fat, (b) this fat accumulated under pressure, and (c) the presence of uncollapsed veins. This conception probably over-simplifies the voluminous, confusing and contradictory literature on the pathogenesis of the subject. Actually the problem is not so lucid. Pulmonary embolism was produced by W[ü]ttig<sup>9</sup> in rabbits with excessive feeding of cod liver oil. Lehman and Moore<sup>10</sup> presented the plausible hypothesis that the fat is derived from the minute particles in the blood fusing into large globules, as is evidenced by the presence of large amounts of fat in the brain and lung following a relatively mild injury.

The method of transportation of the fat is not any clearer than the source of the fat. Busch<sup>11</sup> thought that veins act as avenues of transportation, since after the injection of olive oil with cinnabar into tibial marrow of rabbits, he subsequently found the fat in pulmonary tissues, while the lymphatics and glands contained very little of the material. Gr[ö]ndahl<sup>12</sup> ligated both venous and lymphatic drainage of the extremities of experimental animals and fat embolism occurred.

However, once the fat globules enter the circulation they are filtered through the pulmonary capillaries, and if the globules are of sufficient number they may cause pulmonary edema and hemorrhagic infarction. If the globules pass throughout the lung into the general circulation they produce little or no effect unless they lodge in the brain or heart. Nevertheless cases have been reported where the lungs were free but the systemic circulation contained emboli.

Conclusive evidence of fat embolism as the cause of death cannot be made with certainty, as Lehman and McNattin<sup>13</sup> have shown it to be present in about 50 percent of unselected cadavers. Wright<sup>14</sup> observed fat embolism in 52 of 100 consecutive autopsies, the majority of whom did not have fracture or contusion. Cararra [sic; Carrara]<sup>15</sup> noted fat embolism in 22 percent of cases of cardiovascular-renal disease and 44 percent in cases of burns. Fat within the vessels of the brain, however, is uncommon except in true fat embolism. There is evidence that in adults some fat is mobilized with most if not every fracture and with most surgical damage to bone. Gr[ö]ndahl<sup>12</sup> has shown that fat embolism is directly accountable for not more than one percent of deaths associated with fractures. It has also been noted experimentally with dogs that they will tolerate much larger quantities of fat injected intravenously than could conceivably enter the blood stream in clinical cases. These observations add to the confusion regarding etiology and pathogenesis of fat embolism.

---

*"Cases of fat embolism are of particular interest at the present time with the increase of traumatic injuries due to the expansion of industry and to war casualties."*

---

---

*"Conclusive evidence of fat embolism as the cause of death cannot be made with certainty, as Lehman and McNattin<sup>13</sup> have shown it to be present in about 50 percent of unselected cadavers."*

---

not pictured A. BERNARD GRAY, MD, and NATHAN MEADOFF, MD were orthopedic surgeons in the group of physicians who comprised the staff supplying prepaid health care to workers at the Kaiser shipyard in Richmond, CA during World War II. right JERRY SCHILTZ, MD is Chief of the Department of Orthopedics at the Baldwin Park facility of the Southern California Permanente Medical Group.



---

*"Cutaneous hemorrhages have been frequently reported as characteristic and were present in three of our four cases."*

---



---

*"Since there is no proven successful treatment, prophylaxis is of prime importance."*

---

Fat embolism is commonest in the fourth decade of life. It is believed that fat in the bone marrow is usually insufficient to cause embolism before fourteen years of age, although the youngest case on record is in a baby eight months of age. Alcoholic patients seem more predisposed to the development of fat embolism.

### Symptoms

There is no clinical correlation between the apparent injury and the degree of embolic symptoms. The symptoms usually do not develop for three or four days following the trauma but they may develop earlier. This so-called free interval is fairly characteristic; the shortest interval is thirty minutes, the longest is nine days. Symptoms may be cyclic, corresponding to periodic showers of emboli. It may be impossible to differentiate early symptoms from surgical shock. Late symptoms may resemble postoperative pneumonia. Initial symptoms may be pulmonary or cerebral in character. The characteristic train of symptoms in pulmonary fat embolism is usually ushered in by a rise in temperature and dyspnea. Dyspnea may either become progressively severe or may be extreme at onset of symptoms. Very often the first sign that complications are going to develop may be a clinical presentation of nervousness and excitability. The sputum is frothy and may be blood tinged, but is associated with very little cough. The amount of chest pain varies with extent of infarction. Cyanosis when present varies with the extent of the pulmonary arterial resistance. Great strain is thrown upon the heart, and if the condition progresses the pattern of deep shock and cardiac failure appears. Pulmonary symptoms are absent in about one-third of cases reported. The earliest cerebral manifestations are insomnia, delirium, disorientation, and cortical irritative phenomena consisting of convulsions, rigidity or focal symptoms. Stupor is rapidly followed by an increasing coma, and death usually takes place in three to four days. Signs of increased intracranial pressure have rarely been observed, and the spinal fluid in nearly all cases has been entirely normal.

Cutaneous hemorrhages have been frequently reported as characteristic and were present in three of our four cases. They occurred mainly over the abdomen, chest, shoulders and upper extremities and did not disappear on pressure.

Laboratory procedures of value are few. Sputum examination may be of aid in diagnosis, as free fat droplets may be present in addition to fat-containing alveolar phagocytes. Free fat in the blood has been considered of great diagnostic importance. Lipuria after an injury is of definite diagnostic value, although it is reported as often of late occurrence. In our ex-

perience lipuria has occurred early and has cleared with subsidence of symptoms.

### Treatment

There is no specific treatment for fat embolism, although Rappert<sup>16</sup> in 1939 [sic; 1938], claimed some successful results with sodium desoxycholate injected intravenously to emulsify the fat and reduce blood viscosity. He used 10 cubic centimeters of 20 percent solution every two hours. Further trial of this therapy is indicated. Since there is no proven successful treatment, prophylaxis is of prime importance. Prophylaxis should originate at the site of the accident; (1) in the avoidance of unnecessary or rough handling of patients, (2) immediate splinting and early reduction of all fractures, (3) use of a saw in orthopedic operation instead of a chisel if possible, (4) use of tourniquet and gradual release, with some venous bleeding before complete release. These precautions will lessen the incidence of immediate fat emboli. Other prophylactic measures have been suggested on the basis of experimental evidence. Czerny<sup>17</sup> used venesection during the period of anesthesia to lessen venous congestion. Drainage of the medullary cavity and wound to prevent an increase in pressure is also important whenever feasible. Drainage of the thoracic duct has not been attempted.

**Case 1.** K.W., a 20-year-old white male, was injured on September 14, 1942. A 900-pound lead roll fell off a truck, striking the patient across the anterior aspect of both legs. Thomas splints were applied immediately and the patient was transferred to the hospital by ambulance.

On admission to the hospital, the patient showed no evidence of shock. There was a fracture of the right tibia and fibula at the junction of the middle and lower thirds, with slight displacement, and a bimalleolar fracture of the left ankle.

Three hours after the injury the patient was taken to surgery. Steinman pins were placed through the proximal and distal thirds of the tibia. The fracture was then reduced on the fracture table, and the extremity was immobilized in a cast. The left ankle was reduced and immobilized in a plaster cast. The patient's postoperative course was uneventful until September 18, 1942, four days after the injury, when he exhibited unusual signs of nervousness and restlessness, some pain in the region of the right shoulder blade, and a faint purpuric rash over the trunk and upper limbs. The following day the eruption was more pronounced, and a non-productive cough had developed. The temperature was essentially normal. There was no fat present in the urine. A diagnosis of mild degree of fat embolism was made. The temperature that afternoon rose to 102 degrees Fahrenheit.

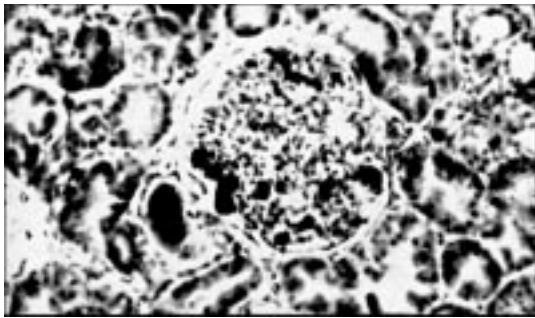


Figure 1. Kidney—Photomicrograph showing fat globules (black areas), especially in glomerular capillaries.

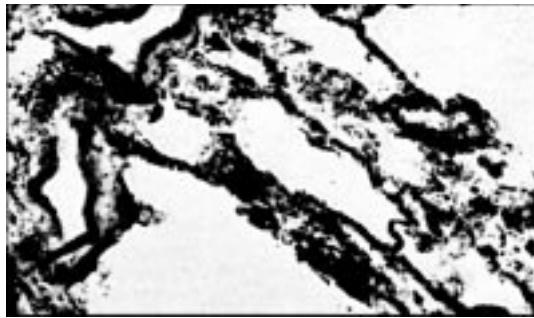


Figure 2. Lung—Photomicrograph showing innumerable fine fat droplets in the alveolar capillaries.

heit with moderately elevated pulse. X-ray examination of the chest revealed an opaque homogenous area in the right subapical region which was apparently due to atelectasis. In the right basal region there was an area of increased pulmonary markings, which suggested bronchopneumonia. The following day the patient raised some bloody sputum, but there was subjective improvement and he seemed brighter. The white blood count was 18,000 cells per cubic millimeter and there was a mild anemia. The patient's symptoms subsided rapidly after that. The temperature came down to normal and the patient made an uneventful recovery.

A diagnosis of fat embolism in this case was established by the presence of fever, respiratory symptoms, and a rash four days after a severe bone trauma. The patient was receiving no drugs that might cause a rash.

**Case 2.** W.D., a 41-year-old white male, was injured about 2 a.m., July 13, 1942, when he was struck across the right leg by a heavy steel plate. The limb was immobilized in a Thomas splint and the patient was transported to a hospital where X-ray examination revealed a simple transverse fracture of the upper third of the shaft of the right femur. Approximately two hours after the injury skeletal traction was instituted, under local anaesthesia, by insertion of a Steinman pin through the left tibia. There was nothing unusual about the patient's condition except, it was noted, that about 14 hours after the injury the patient was unusually apprehensive. About 18 hours after the injury the patient became irrational and incoherent; eight hours later he became stuporous.

Examination about 36 hours after the injury revealed the following: The patient was stuporous and restless, and the upper extremities were in constant motion. Temperature was 100.6 degrees Fahrenheit, pulse rate was 120 per minute, respiratory rate was 20 per minute. There was slight neck rigidity. The lungs revealed diffuse evidence of râles without evidence of consolidation. The blood pressure was 135

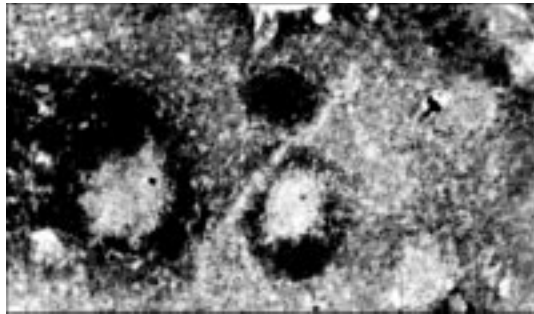


Figure 3. Brain—Photomicrograph showing hemorrhage and necrosis about capillaries occluded by fat emboli. Note capillary in right midfield containing erythrocytes and an irregular black staining fat globule.

millimeters of mercury systolic, 70 diastolic. The skin revealed many fine distinct petechial [h]emorrhages over the chest, neck, and upper arms. There were a few scattered petechiae in the lower extremities and the conjunctivae. Cranial nerve function was intact as far as could be tested. The deep reflexes were hyperactive; the Babinski reflexes were positive. Spinal fluid examination at that time revealed: an initial pressure of 180 millimeters of water, the Queckenstedt test was negative, there were no cells present, the globulin was slightly increased, the Wassermann and gold curve were negative. The red blood cell count was 4.5 million cells per cubic millimeter with 84 percent hemoglobin. The white blood cell count was 19,700 cells per cubic millimeter with 91 percent neutrophils. The urine revealed free fat globules as demonstrated qualitatively. The blood culture was negative.

On July 16, 1942, the coma was deepening and the fever climbing. 300 cc. of 20 percent solution of desoxycholate was given intravenously without any appreciable effect. Sulfathiazole and general supportive stimulant measures had been instituted with the onset of the symptoms without any apparent change in the course of the disease. On July 17,

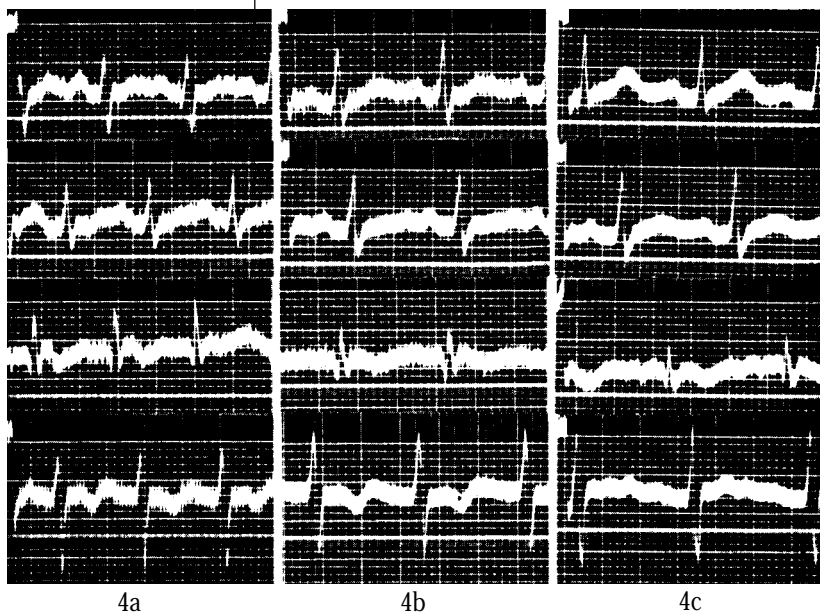


Figure 4a—Electrocardiogram 6 hours after onset of dyspnea and chest pain. Note sinus tachycardia, low voltage, prominent  $S_1$ , inverted  $T_3$  and  $T_4$ .

Figure 4b—Electrocardiogram 24 hours later. Note that  $S_1$  is much less prominent.

Figure 4c—Electrocardiogram 4 days after onset of symptoms. Note  $S_1$  is almost absent,  $T_4$  now upright.

*"A review of the literature reveals that the question of pathogenesis of fat embolism is by no means established."*

1942, the patient developed marked pulmonary edema and died.

Autopsy was performed July 18, 1942. On gross examination the brain surface was hyperemic, and the brain exhibited multiple petechial hemorrhages in sections. Both lungs were congested, and there was a hypostatic pneumonia on the right side. Kidneys revealed general congestion, there was some degree of retroperitoneal hemorrhage with a hematoma involving the bladder wall.

Microscopic examination revealed fat globules present in the capillaries of the lungs, kidneys and brain. (See photomicrographs.)

**Case 3.** G.G., a 19-year-old white male, was injured on April 7, 1943, when he was struck by an automobile. He was immediately transported to the hospital where he was found to have a simple fracture of the right ischium. His general condition was good, there was no evidence of shock or of any complicating condition.

About twenty-eight hours after the injury the patient rather suddenly developed symptoms of dyspnoea and cyanosis. The temperature rose from normal to 102 degrees, the pulse rate increased to 130 per minute, and the respiratory rate to 30 per minute. Physical examination of the lungs revealed no abnormalities, and a roentgenogram of the chest was also negative. A urine specimen voided one hour after the onset of

the acute symptoms revealed the presence of a large amount of fat. A fine petechial rash was first noted about the chest five hours later. The patient was given plasma to combat the apparent circulatory collapse, and sulfadiazine therapy was instituted as an acute pneumonic process could not be entirely ruled out.

About six hours after the onset of the acute episode the temperature returned to normal and the patient seemed much improved. After twenty-four hours the patient's condition appeared normal, the rash had faded, and fat was no longer present in the urine. An uneventful recovery was made.

**Case 4.** Miss D.L.C., a 21-year-old female, had a resection of sclerotic tibial fragments on June 17, 1943. Postoperative condition was normal until forty-eight hours after the surgery when she developed a sudden chill associated with mild shock and pain in the back of the chest. The temperature rose to 104 degrees and the pulse rate to 130 per minute. Dyspnea was moderate, but there were no other abnormal clinical chest findings. Roentgenogram of chest revealed no abnormalities. A presumptive diagnosis of acute fat embolism was made and this was corroborated by the first voided specimen which revealed the presence of a moderate amount of fat. Twenty-four hours after the onset of the acute episode the temperature was down to 100.4 degrees and the patient felt much better. On the fourth day the urine became free of fat and all the acute symptoms had subsided. There was no rash in this case. Serial electrocardiograms were interpreted by the Department of Medicine as showing typical changes of acute cor pulmonale. (See Figure 4.)

#### Summary and Conclusion

1. Four new cases of clinical fat embolism have been presented. Three of these patients recovered; one case terminated fatally.

2. In the two mildest cases the diagnosis was made by the clinical picture of purpura, lipuria, and pulmonary symptoms occurring after a free interval. The patients made excellent progress with expectant treatment.

3. In the fourth case symptoms were more severe, and the clinical picture resembled that of acute pulmonary embolism. There were typical electrocardiographic findings of acute cor pulmonale. The lipuria persisted for three days and disappeared with the relief of symptoms.

4. In the fatal case (case 2), the diagnosis was made with the onset of symptoms, but energetic treatment was to no avail. Cerebral, pulmonary, and renal fat emboli were demonstrated at necropsy.

5. A review of the literature reveals that the question of pathogenesis of fat embolism is by no means established. The theory that the emboli originate at



the site of injury and migrate via the veins, is still the prevalent one.

6. A fairly typical clinical picture of fat embolism may be drawn. This comprises five phases.

(a) The initial period of some degree of shock, attributable to the injury.

(b) The free interval, which may last from a few hours to several days, usually three or four days. During this period the patient seems to be progressing normally.

(c) Pulmonary symptoms develop consisting mainly of dyspnea and some cough with blood-tinged sputum. Symptoms may progress to pulmonary edema and cardiac failure.

(d) Cerebral symptoms vary from early nervousness and excitability, to local or generalized convulsions and coma.

(e) The terminal phase consists of increasing pulmonary edema and cardiac failure, or of increasing stupor, coma, hyperpyrexia and then death.

7. The importance of prophylaxis is stressed, as there are no specific therapeutic measures.

*Photomicrographs by Dr. A.G. Borden*

#### Bibliography

1. Lower, R., cited by Scuderi.<sup>7</sup>
2. Magendie, F., cited by Scuderi.<sup>7</sup>
3. Zenker, F.A., cited by Scuderi.<sup>7</sup>

4. Warthin, A.S.: Traumatic Lipaemia and Fatty Embolism, *Internat. Clin.*, 4:171, 1913.

5. Vance, B.M.: The Significance of Fat Embolism, *Arch. Surg.* 23:426 (Sept.) 1931.

6. Groskloss, H.H.: Fat Embolism, *Yale, J. Biol. and Med.* 8:297, 1936.

7. Scuderi, C.S.: Fat Embolism: Résumé of the Literature Plus Some Newer Thoughts on Diagnosis, *Arch. Surg.* [3]6:614 (April) 1938.

8. Bisgard, J.D., and Baher, C.: Experimental Fat Embolus, *Am. J. Surg.* 47: 466, 1940.

9. Wüttig, H., cited by Winkelman.<sup>18</sup>

10. Lehman, E.P., and Moore, R.M.: Fat Embolism Including Experimental Production without Trauma, *Arch. Surg.* 14:621 (March) 1927.

11. B[u]sch, F., cited by Winkelman.<sup>18</sup>

12. [Grö]ndahl, N.B., cited by Scuderi.<sup>7</sup>

13. Lehman, E.P., and McNattin, R.F.: Fat Embolism: II. Incidence at Postmortem, *Arch. Surg.* 17: 179 (Aug.) 1928.

14. Wright, R.B.: Fat Embolism, *Ann. Surg.* 96:75, 1932.

15. Carrara, M., cited by Scuderi.<sup>7</sup>

16. Rappert, E., cited by Scuderi.<sup>7</sup>

17. Czerny, V., cited by Scuderi.<sup>7</sup>

18. Leathes, J.B., and Raper, H.S.: *The Fats* (2nd ed.), London, Longmans, Green & Co., 1925, p.144.

19. Winkelman, N.W.: Cerebral Fat Embolism, *Arch. Neurol. and Psychiat.* (Jan.) 1942.

20. Strauss, A., cited by Winkelman.<sup>18</sup>

---

*"Although we currently have a greater understanding of the pathophysiology of fat embolism, we are still lacking in understanding the pathogenesis as well as the differences between fat embolism syndrome (FES) and adult respiratory distress syndrome (ARDS)."*

---

#### *Commentary by Jerry Schilz, MD*

Doctors A. Bernard Gray and Nathan Meadoff's article, published during World War II in 1943, begins by stating that there was "particular interest" in fat embolism with the rise of traumatic injuries from war casualties and expansion of industry. They summarized their knowledge of the etiology and pathogenesis of fat embolism and described the usual clinical presentation and treatment. Although we currently have a greater understanding of the pathophysiology of fat embolism, we are still lacking in understanding the pathogenesis as well as the differences between fat embolism syndrome (FES) and adult respiratory distress syndrome (ARDS). We are also still lacking in specific treatment of this disorder and must rely on advanced supportive measures and, of course, on prevention.

Please accept the following as humor not directed at the authors, but at my field of orthopedics and myself. I was tickled to read that "two cases of fat embolism" will be presented and then the report revealed four cases. Also, it is the only time I recall observing tracings of an electrocardiogram in an orthopedic article, but I

was relieved to read that they also required an interpretation from the "Department of Medicine." Humor aside, I commend the authors for a timely description of fat embolism and acknowledge that much of the literature on fat embolism over the years has been reported in the orthopedic journals.

It was interesting to read their description of the "voluminous, confusing, and contradicting literature on the pathogenesis" of FES. Current literature has now clearly described the embolization of marrow products, as well as the inflammatory cascade resulting in alterations of pulmonary function. However, there is still controversy about whether the fat originates from the marrow (embolization theory) or from chylomicra in the blood (intravascular theory). The second theory holds that alteration of fats in the blood leads to formation of large fat droplets which then embolize to the lungs. This hypothesis might explain the occurrence of non-traumatic cases of FES. Persistent confusion is evidenced by the title of a good review article called, "Fat Embolism Syndrome, A Puzzling Phenomenon."<sup>1</sup> It is likely that FES is a vari-

ant of ARDS, with specific differences between them not clear. They have similar etiology, clinical presentation, and treatment. But they differ in severity of lung damage and prognosis with the mortality of FES approximately 10% to 15% and of ARDS approximately 50%. They are now both considered causes of "clinical pneumonitis" or "noncardiogenic edema" and are under the clinical spectrum heading of "acute lung injury."

Other advances such as reaming during intramedullary fixation of fractures or total joint replacements have also advanced our understanding of fat embolism. The use of enlarged insertion holes in the femur and fluted intramedullary instrumentation has decreased the incidence of this complication. There are also data now suggesting a causal relationship between fat embolism and osteonecrosis. With suspense I read the case reports. The authors appeared alert to fat embolism syndrome, and the diagnoses were made quickly after onset of symptoms. However, I was drawn back into time with the report of their fatality, wishing I could offer some modern treatment modalities that have decreased mortality from FES.

The symptoms and signs described in the article are consistent with current descriptions and, although the petechiae are not present in every case, they are now considered diagnostic of FES. As stated, alcoholic patients have been considered more predisposed to FES, but a more recent review<sup>2</sup> noted that patients with higher blood alcohol levels were less likely to develop FES. Laboratory tests have become more numerous and helpful since their original article, but the most important and useful test is still the arterial blood

gas. Other test findings such as low platelet and antiplasmin levels as well as increased antithrombin III, fibrinogen, and plasminogen and complement (C3a & C5a) are predictive of ARDS.

The most helpful advances since the authors' original article have been in the areas of prophylaxis and treatment. They suggested several forms of prophylaxis such as the use of a "chisel" versus a "saw" and the use of a tourniquet. Present day success in prevention is largely due to orthopedic advances and the push for early rigid stabilization of long bone fractures. Once FES has developed, we still have "no specific treatment," but advanced supportive treatment (hydration and ventilatory support) has decreased mortality from 80-100% to a current 10-15%. However, mortality from ARDS is still 50%, and the best treatment is still prevention. Important goals are to treat shock and bleeding immediately and to infuse blood early if needed to prevent overhydration. At present, we see increased likelihood of survival in the face of increased severity of extremity injuries (eg, due to airbags in motor vehicle accidents). It is important to provide early rigid fixation of long bone fractures to decrease the incidence of ARDS. The "importance of prophylaxis is stressed," again, 50 years later. ❖

#### References

1. Gong H Jr. Fat embolism syndrome: A puzzling phenomenon. *Postgrad Med* 1977 Dec; 12(6): 40-48.
2. Petty RW, Galante JO. Circulatory, respiratory, hematopoietic, gastrointestinal, genitourinary, and integumentary systems. In: *Orthopedic Knowledge Update 1*, American Academy of Orthopedic Surgeons 1984; 79-88.

---

*"Laboratory tests have become more numerous and helpful since their original article, but the most important and useful test is still the arterial blood gas."*

---



Sandhill cranes, Bosque del Apache Refuge, near Socorro, New Mexico. Photographed by Janet Neuburg, MD, NWP. Her work can also be found featured on the cover, and on page 43.